

# Mobile Phones: It's Not Just About Brain Tumors!

Head of the INTERPHONE study, Elisabeth Cardis, and scientists in Israel link mobile phones to parotid gland tumors.

## Magda Havas, BSc., PhD

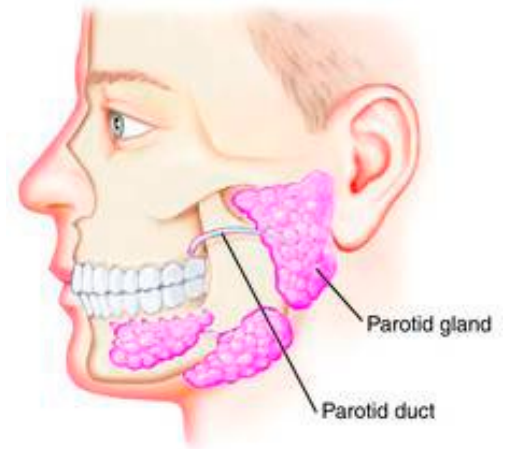
Institute for Health Studies and Environmental & Resource Studies,  
Trent University, Peterborough, ON, Canada.

December 2009

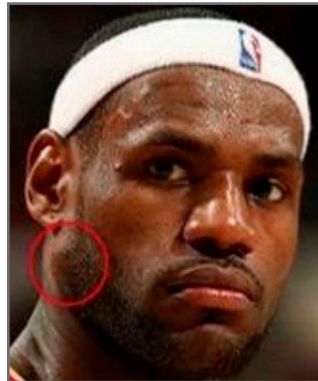[www.MagdaHavas.com](http://www.MagdaHavas.com)

It begins as a lump or mass on the side of the face in front of the ear, at or above the jawbone. If the growth is slow and the lump is painless it is likely to be benign (80% of cases). If the area is painful or numb (nerve paralysis) it may be malignant (20% of cases) and the prognosis is poor with average survival of 2.7 years and a 10-year survival of 14-26%. It affects between 1 to 3 people per 100,000 each year in the Western world. What I am referring to is a parotid gland tumor (PGT), also known as salivary gland tumor (SGT).

Parotid tumors have not received much attention until recently.




Roger Ebert



Lebron James



Adam Yauch



John McCain

**Roger Ebert**, 63, Pulitzer prize-winning movie critic in the Ebert & Roeper show, had his cancerous parotid gland tumor removed June 16, 2006.

**Lebron James**, 24, basketball MVP for the Cleveland Cavaliers, underwent surgery for a benign parotid tumor in June 2009.

**Adam Yauch**, 44, of the Beastie Boys was diagnosed in July 2009 with a malignant parotid tumor and is scheduled for surgery. His band had to cancel engagements as a consequence. [Click here to view his statement on YouTube.](#)

**Senator John McCain** had part of his left parotid gland removed in 2000 although this was in conjunction with removal of lymph nodes as a precautionary step because of his bout with cancer. Recent photographs of John McCain (April 2008) show an enlarged mass on the left side of his face right where his parotid gland is located.



Dr. Siegal Sadetzki testifies at US Senate Hearing for Cell Phones and Health

[Watch the Video on YouTube](#)

[Download the Hi-Res Video](#)

Salivary gland tumors have been associated with ionizing radiation including X-rays and gamma radiation following environmental exposure. For example, survivors of the atomic bomb in Nagasaki and Hiroshima experienced an increase rate in salivary gland tumors. Radiation therapy, including x-ray of the head or radiation for enlarged tonsils in children or for various types of cancers, has also been implicated in this type of tumor, as has inhalation of carcinogens (asbestos mining, plumbing, rubber manufacturing, and wood dust); and various types of viral infections (herpes and possibly HIV).

In 2008, another culprit contributing to PGT was identified – the mobile phone. Dr. Siegal Sadetzki, who testified in September 2009 at a [US Senate Hearing](#) on cell phones, is the Principle Investigator of this report that was based on a Nationwide Israel [CASE CONTROLLED STUDY](#) for the period 2001 to 2003. One of the co-authors of this report, [Elisabeth Cardis](#), is the coordinator of the \$15 million plus dollar, 13-country INTERPHONE epidemiological study of tumor risk for adult mobile phone users. She is also the co-ordinator of the European Commission project [MOBI-Kids](#), which is evaluating the possible association between communication technology and risk of brain tumors in young people.

While previous studies found no association with mobile phone use and PGT, the most recent and largest study to date (Sadetzki et al. 2008) does report such an association. If you read the abstract it is a bit confusing for the average person because it states the following:

“For the entire group, no increased risk of PGTs was observed for ever having been a regular cellular phone user (odds ratio = 0.87; p=0.3) or for any other measure of exposure investigated.” The odds ratio is scientific notation that identifies the degree of risk (above 1 is higher risk and below 1 is lower risk) and the probability value (p) indicates whether this finding is statistically significant (generally when p is less than 0.05 it is considered significant). So the above quote agrees with previous studies that there was no association between salivary gland tumors and cell phone use.

BUT – The very next sentence shows that there is a danger for some individuals and reads: “However, analysis restricted to regular users or to conditions that may yield higher levels of exposure (e.g. heavy use in rural areas) showed consistently elevated risks.”

So what does this elevated risk amount to?

The report states that your risk of getting a parotid tumor on the same side of your head that you use for listening to the mobile phone increases by...

- **34%** if you are a regular cell phone user and have used a mobile phone for 5 years.
- **58%** if you had more than 5,479 calls in your life-time.
- **49%** if you have spoken on the phone for more than 266.3 hours during your life-time.
- **47%** if you have used a mobile phone for 5 years or more and have had more than 5,479 calls in your life-time.
- **50%** if you have used a mobile phone for 5 years or more and have spoken on the phone for more than 266.3 hours.

And if you live in a rural away from major cities area your risk increases by...

- **81%** if you have made more than 18,996 calls in your life-time
- **96%** if you have a life-time exposure of more than 1,035 hours

...since antennas are farther apart, mobile phones have to emit higher levels of radiation to communicate with the nearest cell antenna.

## Other Reports Back Up This Study

A study conducted by the Israeli Dental Association between 1970 and 2006 reports a large increase in cancers of the salivary gland in Israel which may be related to use of cell phones (cited in the daily Haaretz July 2009).

“Between 1980 and 2002, the number of parotid salivary cancers has remained stable at 25 per year, whereas this figure rose to 75 during the next five years,” said Avi Zini, Hadassah School of Dental Medicine. Every fifth patient was under the age of 20. While this study did not include information on cell phone use, researchers plan to collect these data in the next stage of their study.

The message from these reports are the same... the higher the exposure, the longer the exposure, the greater the risk! That is why scientists are finding an association with ipsilateral (same side of the head) tumors generally after 10 years of regular or heavy mobile phone use. This is the case for tumors of the brain (gliomas), the nerve leading to the ear (acoustic neuroma), the eye (uveal melanoma), and now the salivary gland (parotid tumor).

The statement above is also why some studies don't find an association and is the cause for so much confusion in the media... Most studies that find cell phones are safe, allow for an exposure period that

is too short, and the users are defined as anyone who uses a cell phone **at least once a week for 6 months or more**. This dilutes the data in favor of “no effect.” The same logic can be used for cigarettes. We now know tobacco is carcinogenic but we would not expect to find lung cancer among those who smoke one cigarette a week and have been smoking for just over 6 months.

While individuals can reduce their use of mobile phones, or follow the advise of scientists who suggest using hands free or wired air-tube headsets, some of the onus needs to be placed at the feet of the telecom industry that makes huge profits from selling these devices. If mobile phones can be designed to take photographs and videos, to record voices or play music, to tell you where you are and what time it is, then surely they can be re-designed to emit less radiation and to prevent the phone being placed adjacent to the head.

As a scientist, I'm disturbed knowing that policy makers largely ignore studies showing adverse health effects of microwave radiation. What will it take for officials in regulating agencies to recognize that exposing the head to microwave radiation at current levels may be as foolish as X-raying children's feet to fit them with shoes as was done in recent past?

With 4 billion mobile phone users worldwide, if we don't react in a timely fashion to these “early warnings” we will face a human health tsunami. But, unlike natural tsunamis that happen quickly and – once the devastation ends – survivors can rebuild their lives. The microwave tsunami is likely to be a slow, silent, unseen killer taking a few lives at a time. The longer we ignore this threat, the more lives that will be lost, unnecessarily. While I hope I am wrong, I fear... I might be right. Time will tell.

## Sources:

Video of US Senate Hearing courtesy of CSPAN. For a hi-resolution copy of the video seen here please email Magda Havas at [mhavas@trentu.ca](mailto:mhavas@trentu.ca)  
Amiriak, B, HWM Chim, EH Chen, and DW Stepnick. updated Jun 24 2009. Parotid Tumors. <http://emedicine.medscape.com/article/1289616-overview>  
Calabrese, DM and RJ Frey. 2009. <http://www.answers.com/topic/salivary-gland-tumors>  
Hardell, L. M. Carlberg, and K. Hansson Milid. 2009. Epidemiological evidence for an association between use of wireless phones and tumor diseases. Pathophysiology 16(2):113-122. Hardell et al. 2009 article: <http://linkinghub.elsevier.com/retrieve/pii/S0928468009000091>  
Lonn, S, A Ahlbom, HC Christensen, et al. 2006. Mobile phone use and risk of parotid gland tumor. Amer. J. Epid. 164(7):637-643.  
Lonn et al. 2006. article: <http://aje.oxfordjournals.org/cgi/content/abstract/164/7/637>  
National Cancer Institute. viewed December 2009. <http://www.cancer.gov/cancertopics/pdq/treatment/salivarygland/HealthProfessional/page2>  
Sadetzki, S, A Chetrit, A Jarus-Hakak, E Cardis, Y Deutch, S Duvdevani, A Zultan, I Novikov, L Freedman, and M. Wolf. 2008. Cellular phone use and risk of benign and malignant parotid gland tumors—A nationwide case-control study. Amer. J. Epid. 167 (4): 457-467. Sadetzki et al. 2008 article: <http://aje.oxfordjournals.org/cgi/content/abstract/167/4/457>  
Zarbo, R. 2001. Salivary Gland Neoplasia: A review of the practicing pathologist. Mod Pathol 202: 15(3): 298-323. <http://www.nature.com/modpathol/journal/v15/n3/full/3880525a.html>  
Images: [Parotid Gland](#), [Roger Ebert](#), [Lebron James](#), [Adam Yauch](#), [John McCain](#)